ORIGINAL COMMUNICATION

Blood Vessels and Myocardial Thickness within the Left Atrial Appendage Isthmus Line

MATEUSZ K. HOŁDA,[1*†] JAKUB HOŁDA[1†] MARCIN STRONA,[2] MATEUSZ KOZIEJ,[1] AND WIESŁAWA KLIMEK-PIOTROWSKA[1]

[1]*HEART - Heart Embryology and Anatomy Research Team, Department of Anatomy, Jagiellonian University Medical College, Cracow, Poland*

[2]*Department of Forensic Medicine, Jagiellonian University Medical College, Cracow, Poland*

Electric isolation of the left atrial appendage (LAA) and linear ablations in the area of the LAA base are gaining popularity. However, very little is known about the myocardial architecture and the presence of epicardial blood vessels within this region, which could significantly influence the course of such procedures. We examined 200 autopsied hearts (22.5% females, 46.7 ± 16.8 years old). The LAA isthmus (i.e., the line between the LAA ostium and the mitral annulus) was cut longitudinally. The myocardium was thickest at the LAA end of the isthmus (2.4 ± 0.7 mm) followed by its middle sector (2.1 ± 0.7 mm) inside the LAA, 5 mm from its ostium (1.9 ± 0.7 mm), and the mitral annulus end of the isthmus (1.8 ± 0.6 mm) ($P < 0.0001$). At least one artery was found in 96.5% of all samples (89.5% were single branched, 7% had two branches). The great cardiac vein was found in 77.0% and the left marginal vein in 2.5%. The artery was interposed between the endocardium and the great cardiac vein in 31.5% of cases. The smallest distance between the endocardium and the artery was 0.5 mm and between the endocardium and the vein was 0.7 mm. In total, we were able to distinguish fifteen different types of vascular arrangements within the LAA isthmus line in this study. The myocardium within the LAA isthmus is thickest at its LAA end. The left circumflex coronary artery branches are the most frequently-occurring vessels within the isthmus and are present in almost all cases, while the great cardiac vein is present in three quarters of hearts. Clin. Anat. 00:000–000, 2018. © 2018 Wiley Periodicals, Inc.

Key words: left atrial appendage isolation; ablation; great cardiac vein; atrial fibrillation; left atrium; coronary sinus; coronary vessels; atrial appendage; left atrial appendage occlusion; myocardium

INTRODUCTION

The mitral isthmus line remains the most common target for linear ablation adjunct to pulmonary vein isolation in patients with nonparoxysmal atrial fibrillation and for treating left atrial macro re-entrant tachycardia. Nevertheless, because of the insidious anatomy of the mitral isthmus, achieving a complete bidirectional conduction block through the isthmus is technically challenging and frequently impossible (Wittkampf et al., 2005; Cabrera et al., 2012). Failure to achieve complete bidirectional block during mitral

Correspondence to: Mateusz K. Holda, HEART - Heart Embryology and Anatomy Research Team, Department of Anatomy, Jagiellonian University Medical College, Kopernika 12, 31-034 Cracow, Poland. E-mail: jakub.p.holda@gmail.com

[†]These authors contributed equally to the content of this study and are equal first authors of this manuscript.

Received 1 May 2018; Revised 13 June 2018; Accepted 23 June 2018

Published online 00 Month 2017 in Wiley Online Library (wileyonlinelibrary.com). DOI: 10.1002/ca.23242

isthmus ablation could even be proarrhythmogenic (Sawhney et al., 2011). Many alternative strategies and other left atrial endocardial lines have been proposed to overcome this obstacle (Cho et al., 2012; Hayashi et al., 2017; Lee et al., 2017; Maurer et al., 2017).

The left atrial appendage (LAA) lies very close to the mitral isthmus region and its electrophysiological significance is increasingly recognized. Recently, an additional ablation line was proposed, the LAA isthmus, located between the LAA ostium and the mitral valve annulus. This line has two major advantages over the mitral isthmus line: it is significantly shorter and has considerably fewer unwanted structures that can entrap the catheter or cause it to adhere incompletely (Hołda et al., 2016a). Other lines (e.g., the superolateral mitral isthmus line) are also located near the LAA ostium base (Maurer et al., 2017). Furthermore, in about one-third of patients, the LAA can be an important source of initiation, propagation, and recurrence of persistent atrial fibrillation following ablation (Di Biase et al., 2010). Thus, electric isolation of the LAA has been proposed as an adjunct method to improve long-term outcomes in patients with persistent atrial fibrillation (Di Biase et al., 2016; Panikker et al., 2016; Reissmann et al., 2017).

Two main anatomical factors can influence successful LAA isthmus ablation or LAA isolation: (1) the myocardial thickness and (2) the presence of epicardial blood vessels. These two factors were investigated for mitral isthmus area and for predicting ablation failure (Hołda et al., 2016a; Hołda et al., 2018). However, very little is known about them in the LAA isthmus. Therefore, our aim in this study was to investigate the presence and morphometric features of blood vessels and the thickness of the myocardium within the LAA isthmus line.

METHODS

Study Population

We examined 200 autopsied adult human hearts (Caucasian) of both sexes (22.5% females) aged from 17 to 94 (mean = 46.7 ± 16.8) years. The mean body mass index (BMI) of the donors was 25.2 ± 4.6 kg/m^2. Heart specimens were collected during routine forensic medical autopsies at the Department of Forensic Medicine, Jagiellonian University Medical College from July 2013 to January 2018. Hearts were dissected in a routine manner, together with the proximal portions of the great vessels, and blood was washed out. After dissection, the organs were fixed by immersion in 10% paraformaldehyde for a maximum of two months until the time of measurement.

The exclusion criteria included death due to heart failure, severe anatomical defects of cardiovascular system, heart trauma, heart grafts, evident severe macroscopic pathologies of the heart or vascular system found during autopsy, and macroscopic signs of cadaver decomposition. There were no cases with a medical history of any type of arrhythmia.

This study was approved by the Bioethical Committee of Jagiellonian University, Cracow, Poland (No. 122.6120.253.2016). The study protocol conformed to the ethical guidelines of the 1975 Declaration of Helsinki.

Dissection and Measurements

In all hearts, the LAA isthmus (i.e., the shortest line between the inferior margin of the LAA ostium and the mitral valve annulus, Fig. 1A,B) was identified, and its length was measured along the endocardial surface. The diameter of the LAA ostium was measured in two projections: along the axis of the LAA isthmus line and perpendicular to it. The isthmus and the LAA were then cut longitudinally. We divided the LAA isthmus line into three parts: the LAA end (close to the LAA ostium), the middle sector, and the mitral annulus end (close to the mitral valve annulus) (Fig. 1B,C). The maximum thickness of the myocardium was measured at each of these three levels and inside the LAA (5 mm from the LAA ostium).

All blood vessels within the cutting line were then identified and their positions noted. A flexible probe was inserted into the vessels to determine their course and origin. The inner diameters of the main arteries and veins and the shortest distances between vessels were measured. The shortest distances from the margin of the main artery and vein to the (1) endocardial surface of the left atrium, (2) inferior margin of the LAA ostium, and (3) mitral valve annulus were noted. The coronary artery dominance was determined.

To reduce human error, two researchers made all the linear measurements independently using 0.03-mm precision electronic calipers (YATO, YT–7201, Poland). The mean of the two measurements was reported as the final value.

Statistical Analysis

Data are presented as mean ± standard deviation and medians with corresponding lower and upper quartiles (Q1, Q3) for continuous variables, or numbers (percentages) for categorical variables. The Shapiro–Wilk test was used to determine whether the quantitative data were normally distributed. Continuous parameters were compared using the Mann–Whitney *U* test or the nonparametric analysis of variance (Kruskal–Wallis) test. Correlation coefficients were calculated to measure the statistical relationships among the parameters of the measured hearts. Qualitative variables were compared using the χ^2 test of proportions for categorical variables. STATISTICA v13.1 (StatSoft Inc., Tulsa, OK) was used for statistical analyses. *P*-values <0.05 were considered statistically significant.

RESULTS

The mean heart weight was 434.1 ± 95.7 g. The right coronary artery was dominant in 87.5% of

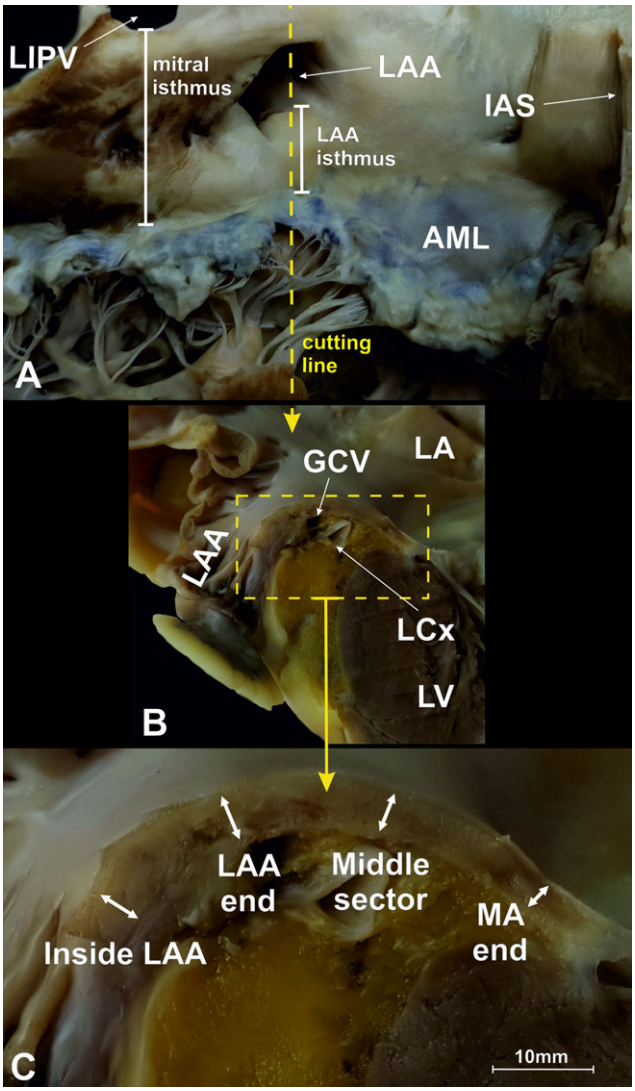

Fig. 1. Photographs of cadaveric heart specimens showing studied area. (A) The left atrium is open and the venous part is dissected. The mitral and left atrial appendage (LAA) isthmuses are visible. (B) Cross-section along the LAA isthmus line. (C) The schematic division into three sectors and measurements of myocardial thickness within the LAA isthmus line are shown. AML, anterior mitral leaflet; GCV, great cardiac vein; IAS, inter atrial septum; LA, left atrium; LCx, left circumflex artery; LIPV, left inferior pulmonary vein; LV, left ventricle; MA, mitral valve annulus. [Color figure can be viewed at wileyonlinelibrary.com]

cases, the left coronary artery in 10.5%, and there was balanced circulation in 2.0%. The mean length of the LAA isthmus was 14.0 ± 4.7 mm. The mean LAA diameter was 12.1 ± 4.4 mm measured along the axis of the LAA isthmus line and 13.0 ± 4.6 mm perpendicular to it. Within the LAA isthmus, the myocardium was thickest at the LAA end (2.4 ± 0.7 mm) followed by the middle sector (2.1 ± 0.7 mm) and thinnest near the mitral annulus end (1.8 ± 0.6 mm) ($P < 0.0001$) (Fig. 2). The myocardial thickness at the LAA isthmus mitral annulus end was positively correlated with heart weight ($r = 0.21$, $P = 0.007$) and was significantly greater in males than females (1.8 ± 0.6 vs.1.5 ± 0.4 mm, $P = 0.0001$). The mean myocardial thickness inside the LAA was 1.9 ± 0.7 mm and was positively correlated with the thickness at the LAA end of the isthmus ($r = 0.20$, $P = 0.005$).

Within the LAA isthmus line, at least one artery was found in 96.5% of all samples. A single branch was found in 89.5% of all hearts (Fig. 3A,B) and a double branch in 7.0%. All were branches of the left circumflex artery. The mean diameter of the single branch artery was 2.6 ± 0.9 mm. When a doubled artery was present there was no difference in the branch diameters (2.6 ± 0.6 vs.2.3 ± 0.6 mm, $P > 0.05$). The main artery diameter was positively correlated with the myocardium thickness at the LAA end of the isthmus ($r = 0.22$, $P = 0.007$) and donor age ($r = 0.27$, $P < 0.0001$).

A single vein identified as a great cardiac vein (Figs. 1C and 3A) was found in 74.5% of all hearts; in 2.5%, two veins were found, a great cardiac vein and a left marginal vein. The mean diameter of the great cardiac vein was 2.6 ± 1.0 mm while the left marginal vein was significantly smaller (1.4 ± 0.2 mm, $P = 0.006$). No blood vessels were observed in 1.0% of specimens (Fig. 3D).

On the basis of vessel types and locations, we were able to distinguish different types of vasculature arrangements within the LAA isthmus line as presented in Figure 4. All vessels were located in epicardial adipose tissue. The artery was interposed between the endocardial surface and the great cardiac vein in 31.5% of all cases (Fig. 3A). A vein located between the left atrial endocardium and the coronary artery was found in 15.5%.

Table 1 presents the morphometric relationship between the great cardiac vein, the single branch artery, the epicardial surface of the left atrium, the mitral valve annulus, and the LAA ostium. The smallest distance between the endocardial surface and the artery (0.5 mm) was observed when two branches were present. The smallest observed distance between the vein and the endocardial surface was 0.7 mm (for the great cardiac vein). The great cardiac vein was located closer than 2 mm from the endocardial surface in 8.5% and closer than 3 mm in 21.5% of all hearts. For the artery, the corresponding values were 13.0% and 35.5%, respectively.

There were no other significant sex differences in any of the measured parameters. There were also no other significant correlations between the measured parameters and donor age, BMI, or heart weight.

DISCUSSION

The myocardium, especially its thickness and architecture, plays a key role in ablation procedures. A thinner myocardium inside the mitral isthmus is associated with immediate success in peri-mitral

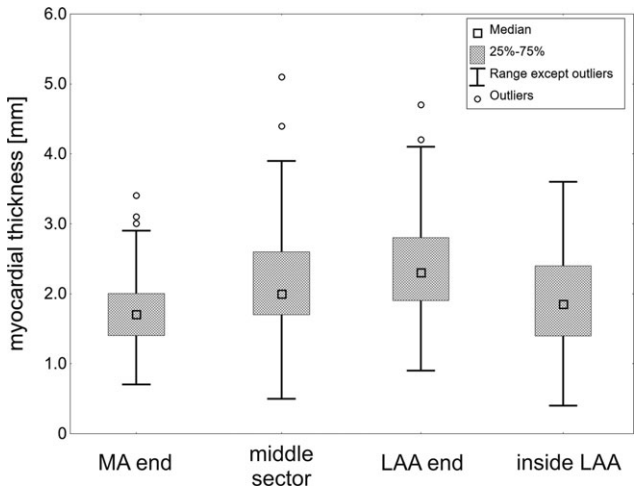

Fig. 2. Box-and-Whiskers plot of myocardial thickness median values in different sectors of the left atrial appendage (LAA) isthmus line and inside the LAA. MA, mitral valve annulus.

flutter ablation (Latcu et al., 2016). However, thinner tissue requires lower ablation energy and can be a factor contributing to perforation of the left atrium wall. Conversely, a thicker wall is associated with a higher failure rate, though it is much safer. When the myocardial architecture inside the LAA isthmus is compared with the mitral isthmus of their corresponding sectors, we conclude that the myocardium is significantly thicker in the superior (or the LAA or pulmonary vein) sector of the LAA than the mitral isthmus (2.4 ± 0.7 vs.1.9 ± 1.0 mm, $P < 0001$). These proportions are reversed for the middle (2.1 ± 0.7 vs.3.0 ± 1.5 mm, $P < 0.0001$) and inferior (or mitral annulus) sectors (1.8 ± 0.6 vs.2.7 ± 1.3 mm, $P < 0.0001$) (Hołda et al., 2018). Moreover, in 95.5% of cases, the LAA isthmus is devoid of additional, differently-organized muscular and membranous structures (e.g., crevices, recesses, muscular bridges) while they are present in the mitral isthmus in 34.5% of hearts (Hołda et al., 2016a). The main fear associated with procedures inside or around the LAA is the risk of perforation because of the very thin walls of the appendage (Cabrera et al., 2008). This can also be true for the right atrial appendage, where the wall in large areas consists of only conjoined endocardium and epicardium with no muscular layer. The wall of the LAA is more solid than that of the right atrial appendage. The region near the LAA ostium is especially at risk since it is rich in trabeculae. The mean myocardial thickness inside the LAA measured in this study was 1.9 ± 0.7 mm (0.5–3.6 mm), which is comparable to the thickness at the mitral annulus end of the LAA isthmus and the pulmonary vein end of the mitral isthmus. It should also be emphasized that the article-thin atrial wall, which is usually observed in the mitral isthmus area (especially inside the crevices or recesses), rarely appears within the LAA isthmus region, where the wall is significantly thicker (Cabrera et al., 2008; Hołda et al., 2016a). Also, in the region of the cavotricuspid isthmus, we should expect a very thin area within the posterior (or membranous) part of the isthmus (Klimek-Piotrowska et al., 2016). No segmental narrowing of the left atrial wall is observed in the LAA isthmus, which is common for the middle sector of the mitral isthmus (7.5% of all cases), where the whole atrial wall is <0.8 mm thick (Hołda et al., 2018). The myocardium of the LAA ostium base is covered by a relatively thick layer of epicardial adipose tissue, which does not extend over the LAA body.

The detailed arrangement and morphometry of the vasculature in the region of the LAA isthmus is poorly understood (Wittkampf et al., 2005). The artery is present within the LAA line in almost all cases (96.5%), but only in 57.0% in the mitral isthmus line (Hołda et al., 2018). The prevalence of the left circumflex artery decreases gradually in further sections of the atrioventricular groove (Randhawa et al., 2016). The mean diameter of the artery also gradually decreases, and there is already a significant difference within the mitral isthmus line (2.6 ± 0.9 vs.2.3 ± 1.0 mm, $P = 0.01$) (Hołda et al., 2018). The

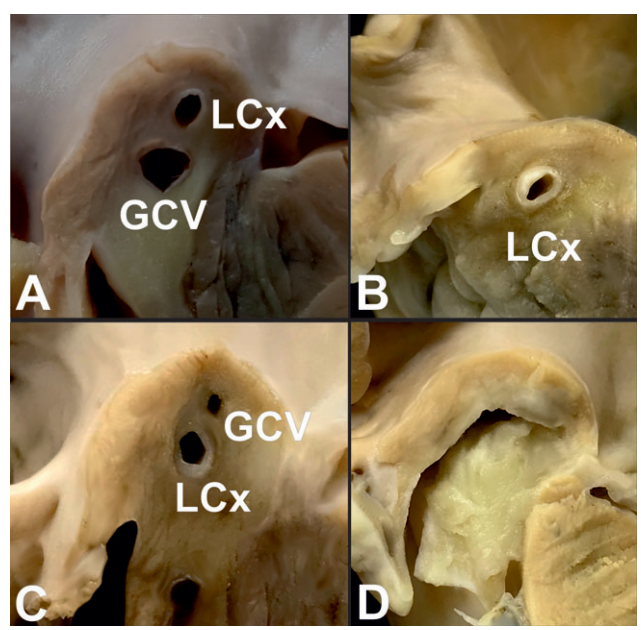

Fig. 3. Photographs of cadaveric heart specimens; the left atrial appendage (LAA) isthmus line is cut longitudinally. (A) The most common type of blood vessel arrangement in the LAA isthmus; the artery is located between the left atrium endocardial surface and the vein (26.5%). (B) The second most common variant of LAA morphology—only the artery could be seen within the LAA isthmus line (22.0%). (C) The vein is interposed between the left atrium endocardial surface and the artery (10.5%). (D) The LAA isthmus without blood vessels within the isthmus line. GCV, great cardiac vein; LCx, left circumflex artery. [Color figure can be viewed at wileyonlinelibrary.com]

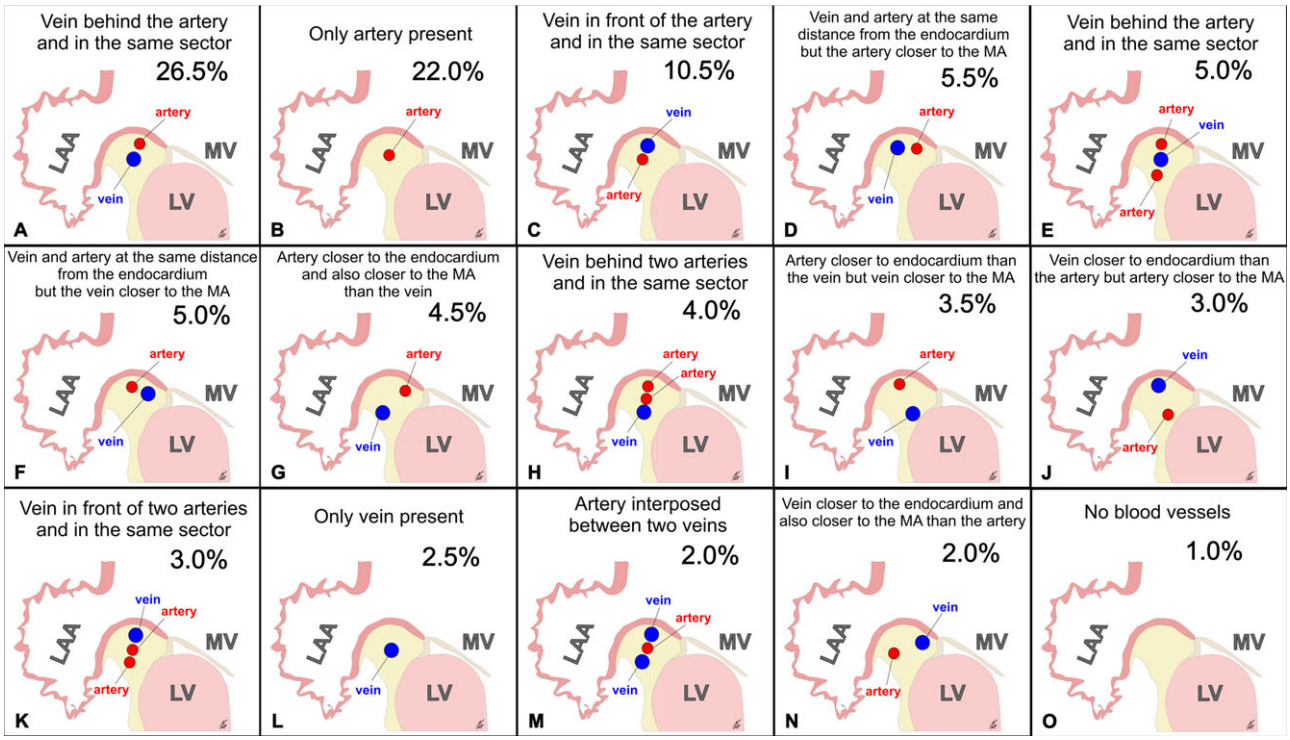

Fig. 4. Schematic view of the left atrial appendage (LAA) isthmus line section Fifteen different types of spatial relationship of main blood vessels within the mitral isthmus line (in relation to the endocardium) are shown (N = 200). LV, left ventricle; MA, mitral valve annulus. [Color figure can be viewed at wileyonlinelibrary.com]

presence of the left circumflex artery within the left atrial wall can be clinically highly significant during ablation procedures. It is mainly undesirable because thermal injury and acute occlusion of the artery can be serious complications (Wong et al., 2011b). For this reason, the radiofrequency energy delivered might have to be lowered. Conversely, the artery can have a "heat-sink" effect caused by the rapid arterial blood flow draining energy from the ablation site; thus, an increase in radiofrequency energy can be justified (Wong et al., 2011a).

The great cardiac vein was found within the LAA isthmus area in 75% of patients, and in almost all hearts within the mitral isthmus section and closer to the interatrial septum parts of the left atrial wall (whether the great cardiac vein or the coronary sinus) (Randhawa et al., 2016; Hołda et al., 2018). Not surprisingly, the venous vessel was narrower within the LAA isthmus than the mitral isthmus (2.6 ± 1.0 vs.4.1 ± 1.2 mm, $P < 0.0001$). This is because a larger venous diameter entails the need for a significantly increased delivery of radiofrequency energy, and with total ablation time, a narrower vein less likely to be near the LAA is beneficial (Wong et al., 2011a). Moreover, the myocardial sleeves around the coronary venous system vessels can act as an epicardial connection bridging the ablation lesion line and thus contributing to ablation failure (Saremi et al., 2011). However, such connections are mainly characteristic of the coronary sinus (closer to its right atrial

TABLE 1. Dimensions of the Main Blood Vessels Identified Within the Left Atrial Appendage (LAA) Isthmus Line and Their Relations to the Endocardial Surface, Mitral Valve Annulus (MA), and LAA Ostium

	N	Mean	SD	Min	Max	Median	Q1	Q3
Artery* to MA distance (mm)	179	4.0	2.2	0.1	15.1	4.3	2.7	5.6
Artery* to LAA ostium distance (mm)	179	9.0	3.6	2.9	18.9	9.3	6.6	11.4
Artery* to endocardial surface distance (mm)	179	3.6	2.6	0.5	14.9	4.2	2.5	5.1
GCV to MA distance (mm)	154	3.4	2.8	0.2	15.1	4.0	2.0	5.5
GCV to LAA ostium distance (mm)	154	9.3	3.9	2.0	25.0	9.5	6.2	12.0
GCV to endocardial surface distance (mm)	154	5.2	3.3	0.7	16.3	5.6	2.8	7.7
Artery* to GCV distance (mm)	149	3.6	2.6	0.5	14.9	4.2	2.5	5.1

GCV, great cardiac vein; N, number of samples; Q_1 and Q_3, lower and upper quartiles; *, single branch artery.

ostium) and should not occur in the LAA area (Chauvin et al., 2000).

The main observable difference between the mitral isthmus and the LAA isthmus is the presence of the left circumflex artery without the accompanying venous vessels in the latter area in 22% of hearts (Fig. 4B) but not in the former area (Hołda et al., 2018). Such a configuration (absence of vein) can facilitate ablation since the vein is mainly responsible for convective cooling. Conversely, absence of the vein prevents epicardial ablation in this area. Moreover, there is a high risk of thermal injury to the artery in this arrangement. The most unwanted configuration is the so-called interposed artery (i.e., the artery located between the endocardium and the vein), which is present in the LAA isthmus in 31.5% of all cases (Fig. 4A,E) and in the mitral isthmus in only 15.0% (Hołda et al., 2018). It is a predictor of unsuccessful linear ablation during both endocardial and epicardial approaches. Arterial injury is highly likely when the epicardial ablation is performed from the coronary venous system in this variant. When the vein is located between the endocardium and the artery (Fig. 4C,K,M), endocardial ablation is relatively safe, but owing to the great cooling capacities of the vein located near the endocardial surface, more energy needs to be provided to achieve complete bidirectional conduction block across the isthmus. Epicardial ablation from within the venous system is relatively safe and efficient under such conditions, but there is still a risk of arterial injury.

The proximity between the left circumflex artery and the LAA ostium can have another clinical implication resulting from implanting the LAA closure device. The minimum observed distance between the artery and the LAA is 2.9 mm (Table 1). If the LAA occluder is oversized or inadequately positioned, left circumflex coronary artery compression and critical occlusion can result. This is especially dangerous in patients whose sinoatrial node artery originates from the left circumflex artery. It should also be emphasized that the blood vessels run significantly above the mitral valve annulus; therefore, this structure cannot be used to determine the positions of vasculature.

This study has several limitations. The main limitation is that all measurements and observations were made on autopsied heart specimens after paraformaldehyde fixation, which could affect tissue size. However, previous studies have shown that 10% paraformaldehyde does not cause atrial tissue dimensions to differ significantly from those before fixation (Hołda et al., 2016b). Another limitation is that we are unable to draw conclusions about the behavior and dimension changes of the studied area within the cardiac cycle. Finally, the heart specimens were obtained from healthy donors without atrial fibrillation or other forms of arrhythmia; thus, our results only represent the normal anatomy of the studied region. It is well known that long-lasting atrial fibrillation can lead to left atrial remodeling, significantly changing its dimensions. Nevertheless, this should not affect the arrangement of blood vessels within the LAA ostium base.

CONCLUSIONS

The myocardium within the LAA isthmus is thickest at its LAA end. Also, while the myocardium inside the LAA is not thinnest along the LAA isthmus line, lack of external support from epicardial tissue can entail a perforation risk in this area during ablation. Left circumflex coronary artery branches are the vessels that occur most frequently within the isthmus and are present in almost all cases, while the great cardiac vein is present in 75% of all hearts. Knowledge of the most common blood vessel variants in the LAA isthmus area and their preprocedural imaging can help to increase the safety and efficiency of various procedures in this region.

ACKNOWLEDGMENTS

We are extremely grateful to the individuals (and their families) who donated their bodies to science. Dr Mateusz Hołda was supported by the Foundation for Polish Science (FNP). The funders had no role in the study's design, data collection or analysis, decision to publish, or preparation of the manuscript.

CONFLICT OF INTEREST

None.

REFERENCES

Cabrera JA, Ho SY, Climent V, Sánchez-Quintana D. 2008. The architecture of the left lateral atrial wall: A particular anatomic region with implications for ablation of atrial fibrillation. Eur Hear J 29: 356–362.

Cabrera JA, Pizarro G, Sánchez-Quintana D. 2012. Muscular architecture of the mitral isthmus: Anatomical determinants for catheter ablation. Europace 14:1069–1071.

Chauvin M, Shah DC, Haïssaguerre M, Marcellin L, Brechenmacher C. 2000. The anatomic basis of connections between the coronary sinus musculature and the left atrium in humans. Circulation 101: 647–652.

Cho Y, Lee W, Park EA, Oh IY, Choi EK, Seo JW, Oh S. 2012. The anatomical characteristics of three different endocardial lines in the left atrium: Evaluation by computed tomography prior to mitral isthmus block attempt. Europace 14:1104–1111.

Di Biase L, Burkhardt JD, Mohanty P, Mohanty S, Sanchez JE, Trivedi C, Günes, M, Gökoğlan Y, Gianni C, Horton RP, Themistoclakis S, Gallinghouse GJ, Bailey S, Zagrodzky JD, Hongo RH, Beheiry S, Santangeli P, Casella M, Dello Russo A, Al-Ahmad A, Hranitzky P, Lakkireddy D, Tondo C, Natale A. 2016. Left atrial appendage isolation in patients with longstanding persistent AF undergoing catheter ablation: BELIEF Trial. J Am Coll Cardiol 68:1929–1940.

Di Biase L, Burkhardt JD, Mohanty P, Sanchez J, Mohanty S, Horton R, Gallinghouse GJ, Bailey SM, Zagrodzky JD, Santangeli P, Hao S, Hongo R, Beheiry S, Themistoclakis S, Bonso A, Rossillo A, Corrado A, Raviele A, Al-Ahmad A, Wang P, Cummings JE, Schweikert RA, Pelargonio G, Dello Russo A, Casella M, Santarelli P, Lewis WR, Natale A. 2010. Left atrial appendage: An underrecognized trigger site of atrial fibrillation. Circulation 122:109–118.

Hayashi K, Heeger C-H, Saguner AM, Mathew S, Maurer T, Lemes C, Riedl J, Sohns C, Santoro F, Reissmann B, Tilz RR, Metzner A, Kuck K-H, Ouyang F. 2017. Catheter ablation of the superolateral mitral isthmus line: A novel approach to reduce the need for epicardial ablation. Circ ArrhythmElectrophysiol 19:iii230.

Hołda MK, Klimek-Piotrowska W, Koziej M, Piątek K, Hołda J. 2016b. Influence of different fixation protocols on the preservation and dimensions of cardiac tissue. J Anat 229:334–340.

Hołda MK, Koziej M, Hołda J, Tyrak K, Piątek K, Bolechała F, Klimek-Piotrowska W. 2016a. Anatomic characteristics of the mitral isthmus region: The left atrial appendage isthmus as a possible ablation target. Ann Anat 210:103–111.

Hołda MK, Koziej M, Holda J, Tyrak K, Piatek K, Krawczyk-Ozóg A, Klimek-Piotrowska W. 2018. Spatial relationship of blood vessels within the mitral isthmus line. Europace 20:706–711.

Klimek-Piotrowska W, Hołda MK, Koziej M, Hołda J, Piątek K, Tyrak K, Bolechała F. 2016. Clinical Anatomy of the Cavotricuspid Isthmus and Terminal Crest. Plos One 11:e0163383.

Latcu DG, Squara F, Massaad Y, Bun SS, Saoudi N, Marchlinski FE. 2016. Electroanatomic characteristics of the mitral isthmus associated with successful mitral isthmus ablation. Europace 18:274–280.

Lee JH, Nam G-B, Kim M, Hwang YM, Hwang J, Kim J, Choi K-J, Kim Y-H. 2017. Radiofrequency catheter ablation targeting the vein of marshall in difficult mitral isthmus ablation or pulmonary vein isolation. J Cardiovasc Electrophysiol 28:386–393.

Maurer T, Metzner A, Ho SY, Wohlmuth P, Reißmann B, Heeger C, Lemes C, Hayashi K, Saguner AM, Riedl J, Sohns C, Mathew S, Kuck KH, Wissner E, Ouyang F. 2017. Catheter Ablation of the Superolateral Mitral Isthmus Line: A Novel Approach to Reduce the Need for Epicardial Ablation. Circ Arrhythm Electrophysiol 10: pii: e005191.

Panikker S, Jarman JWE, Virmani R, Kutys R, Haldar S, Lim E, Butcher C, Khan H, Mantziari L, Nicol E, Foran JP, Markides V, Wong T. 2016. Left atrial appendage electrical isolation and concomitant device occlusion to treat persistent atrial fibrillation: A first-in-human safety, feasibility, and efficacy study. Circ ArrhythmElectrophysiol 9:e003710.

Randhawa A, Saini A, Aggarwal A, Saikia UN, Tubbs RS, Gupta T, Rohit MK, Kalyan GS, Sahni D. 2016. Spatial relationship of coronary sinus-great cardiac vein to mitral valve annulus and left circumflex coronary artery: Implications for cardiovascular interventional procedures. Cardiovasc Pathol 25:375–380.

Reissmann B, Rillig A, Wissner E, Tilz R, Schlüter M, Sohns C, Heeger C, Mathew S, Maurer T, Lemes C, Fink T, Wohlmuth P, Santoro F, Riedl J, Ouyang F, Kuck K-H, Metzner A. 2017. Durability of wide-area left atrial appendage isolation: Results from extensive catheter ablation for treatment of persistent atrial fibrillation. Hear Rhythm 14:314–319.

Saremi F, Thonar B, Sarlaty T, Shmayevich I, Malik S, Smith CW, Krishnan S, Sánchez-Quintana D, Narula N. 2011. Posterior interatrial muscular connection between the coronary sinus and left atrium: Anatomic and functional study of the coronary sinus with multidetector CT. Radiology 260:671–679.

Sawhney N, Anand K, Robertson CE, Wurdeman T, Anousheh R, Feld GK. 2011. Recovery of mitral isthmus conduction leads to the development of macro-reentrant tachycardia after left atrial linear ablation for atrial fibrillation. Circ Arrhythm Electrophysiol 4:832–837.

Wittkampf FH, Oosterhout MF, van Loh P, Derksen R, Vonken EJ, Slootweg PJ, Ho SY. 2005. Where to draw the mitral isthmus line in catheter ablation of atrial fibrillation: Histological analysis. Eur Hear J 26:689–695.

Wong KC, Jones M, Sadarmin PP, Bono J, De Qureshi N, Rajappan K, Bashir Y, Betts TR. 2011. Larger coronary sinus diameter predicts the need for epicardial delivery during mitral isthmus ablation. Europace 13:555–561.

Wong KC, Lim C, Sadarmin PP, Jones M, Qureshi N, Bono J, De Rajappan K, Bashir Y, Betts TR. 2011. High incidence of acute sub-clinical circumflex artery "injury" following mitral isthmus ablation. Eur Hear J 32:1881–1890.