Annals of Anatomy 210 (2017) 103–111

Contents lists available at ScienceDirect

Annals of Anatomy

journal homepage: www.elsevier.com/locate/aanat

RESEARCH ARTICLE

Anatomic characteristics of the mitral isthmus region: The left atrial appendage isthmus as a possible ablation target

Mateusz K. Hołda[a,b,*,1], Mateusz Koziej[a,b], Jakub Hołda[a,b], Kamil Tyrak[a,b], Katarzyna Piątek[a,b], Filip Bolechała[c], Wiesława Klimek-Piotrowska[a,b]

[a] Department of Anatomy, Jagiellonian University Medical College, Cracow, Poland
[b] HEART—Heart Embryology and Anatomy Research Team, Jagiellonian University Medical College, Cracow, Poland
[c] Department of Forensic Medicine, Jagiellonian University Medical College, Cracow, Poland

ARTICLE INFO

Article history:
Received 27 September 2016
Received in revised form 30 October 2016
Accepted 22 November 2016

Keywords:
Atrial anatomy
Atrial fibrillation
Left atrial appendage isthmus
Left atrial isthmus
Lateral isthmus
Linear ablation
Peri-mitral atrial flutter

ABSTRACT

The mitral isthmus is a part of the postero-inferior area of the lateral left atrial wall located between the mitral annulus and the left inferior pulmonary vein ostium. Linear ablation lesions are created within the mitral isthmus for the invasive treatment of left atrial arrhythmias. However, the anatomy of this region is not fully understood. The aim of this study has been to provide a detailed morphometric description of the mitral isthmus region and to propose another possible isthmus within the investigated heart area that may serve as a potential new ablation target. Two hundred autopsied, non-atrial fibrillation hearts (23.5% deriving from females) whose donors were a mean of 47.6 ± 17.6 years old were investigated. We macroscopically assessed the anatomy of the postero-inferior area of the lateral left atrial wall. The mean mitral isthmus length was 28.8 ± 7.0 mm and was significantly longer than the left atrial appendage (LAA) isthmus (14.2 ± 4.8 mm) ($p = .00$). The distance between the LAA orifice and the left inferior pulmonary vein ostium (18.4 ± 4.8 mm) was longer than the LAA isthmus ($p = .00$) and shorter than the mitral isthmus ($p = .00$). The LAA isthmus was longer in hearts with a common left pulmonary vein ($p = .037$). In 65.5% of all cases the area between the right and left mitral isthmus lines was completely smooth. In the remaining hearts, crevices and diverticula (18.0%), intertrabecular recesses (7.0%), trabecular bridges (3.5%), or co-existence of these structures (6%) could be observed. The LAA isthmus line was smooth in 95.5% of all cases, with only small crevices in the remaining 4.5%. In conclusion, regardless of the anatomical variants of the left-sided pulmonary veins, the mitral isthmus area is quite uniform in size. The LAA isthmus is considerably shorter than the mitral isthmus. The mitral isthmus line has many unwanted structures that may entrap the catheter, which is not the case for the LAA isthmus. We proposed the LAA isthmus line for potential clinical use.

1. Introduction

Based solely on their clinical observation, in 2001 Luria et al. defined a new concept, the left atrial isthmus. Located in the infero-lateral left atrium of the human heart, the left atrial isthmus was described as a narrow isthmus of conductive tissue (anatomic or functional) bounded by the infero-lateral mitral valve annulus and the left inferior pulmonary vein (LIPV) (Luria et al., 2001). The first anatomical description of the left atrial isthmus was carried out three years later by Becker (2004), who studied 20 autopsied hearts. The left atrial isthmus name quickly became interchangeable with other terms, such as: mitral-pulmonary isthmus, lateral left atrial isthmus, or mitral isthmus, the latter being the most common one at present (Chiang et al., 2006; de Vasconcelos et al., 2002; Oral et al., 2003).

The clinical importance of the mitral isthmus region cannot be overstated. The pulmonary vein isolation is the standard approach to drug refractory paroxysmal atrial fibrillation (AF) (Calkins et al., 2012). Catheter ablation for persistent AF is more difficult and is associated with less favorable results (Kirchhof and Calkins, 2016). To improve the efficacy of pulmonary vein isolation and prevent AF recurrence, several adjuvant lineal lesions were proposed inside the left atrium (Calkins et al., 2012). The mitral isthmus ablation quickly became one of the most commonly performed technique and showed good efficacy (Wong and Betts, 2012). Even though the

* Corresponding author at: Department of Anatomy, Jagiellonian University Medical College, Kopernika 12, 31-034 Cracow, Poland. Fax: +48 12 422 95 11.
E-mail addresses: mkh@onet.eu, mateusz_holda@onet.eu (M.K. Hołda).
[1] http://www.heart.cm.uj.edu.pl/.

http://dx.doi.org/10.1016/j.aanat.2016.11.011
0940-9602/

latest STAR AF II trial found no reduction in the rate of recurrent AF in patients with persistent AF when linear ablation was performed in addition to pulmonary vein isolation, the mitral isthmus line is still a commonly-used ablation site (Verma et al., 2015). It is also an effective treatment option for peri-mitral flutter (Matsuo et al., 2010).

The mitral isthmus is an example of a case in which the clinical usage of a particular heart region and the introduction of invasive techniques outpaced its detailed morphological description and full basic understanding. Mitral isthmus ablation is a challenging procedure and creating an incomplete lesion could be counterproductive and even proarrhythmogenic (Matsuo et al., 2010). Only achieving a continuous ablation line and bidirectional conduction block between the LIPV and the lateral mitral annulus may interrupt the macro-reentrant circuits and benefit patients with left atrial arrhythmias (Wong and Betts, 2012). A thorough understanding of the anatomical conditions is essential for safe and efficacious mitral isthmus ablation, as a lack of familiarity can cause many serious complications. Thus, the purpose of this study is to provide a detailed morphometric description of the infero-lateral left atrium wall.

Despite its proven effectiveness, the mitral isthmus line is not the perfect site for creating linear ablation lesions. Also, many other lines were proposed as alternatives to the mitral isthmus (Wong and Betts, 2012). However, they were found to have a less favorable anatomy and unsatisfactory clinical results. Hence, the second aim of this study has been to find another possible isthmus within the investigated heart region that may serve as a potential new ablation target.

2. Material and methods

2.1. Study population

We focused on 200 randomly-selected autopsied human hearts from adult Caucasian individuals of both sexes (23.5% female) aged 17–94 (mean = 47.6 ± 17.6 years). The average body mass index (BMI) of the individuals was 26.8 ± 4.5 kg/m^2, and the average body surface area (BSA) was 1.9 ± .2 m^2. The hearts were collected during routine forensic medical autopsies. The primary cause of death included: suicide, murder, traffic accident, and home accident. The difference in sex distribution (F = 23.5% vs M = 76.5%) results from the forensic nature of death, which is more common in males. The exclusion criteria included severe anatomical defects, heart grafts, evident severe macroscopic pathologies of the heart or vascular system found during autopsy, heart trauma, and macroscopic signs of cadaver decomposition. No death due to heart failure was observed. There were no cases with a past medical history of any type of arrhythmia. This study was approved by the Bioethical Committee of Jagiellonian University Medical College, Cracow, Poland. The study protocol conforms to the ethical guidelines of the 1975 Declaration of Helsinki.

2.2. Dissection and measurements

The hearts were dissected together with the proximal portions of the great vessels: the ascending aorta, pulmonary trunk, superior and inferior vena cava, and all of the pulmonary veins. We weighed the hearts before fixation using a .5 g precision electronic laboratory scale (SATIS, BSA-L Laboratory, Poland). After dissection, all of the hearts were fixed by immersion in 10% paraformaldehyde solution for a maximum of two months until the time of measurement (Hołda et al., 2016).

The left atrium was opened in a routine way, using an incision between right and left pulmonary veins extending from the superior pulmonary veins through the left atrial roof to its anterior wall. If necessary, additional cuts were made to better present the investigated area. We obtained linear measurements using .03-mm YATO (YT–7201) precision electronic calipers. All measurements were made by two independent researchers in order to reduce bias. If the differences in the results obtained by the two researchers exceeded 10%, both of the measurements were repeated. The mean of the two measurements was calculated, with approximation to the tenth decimal place.

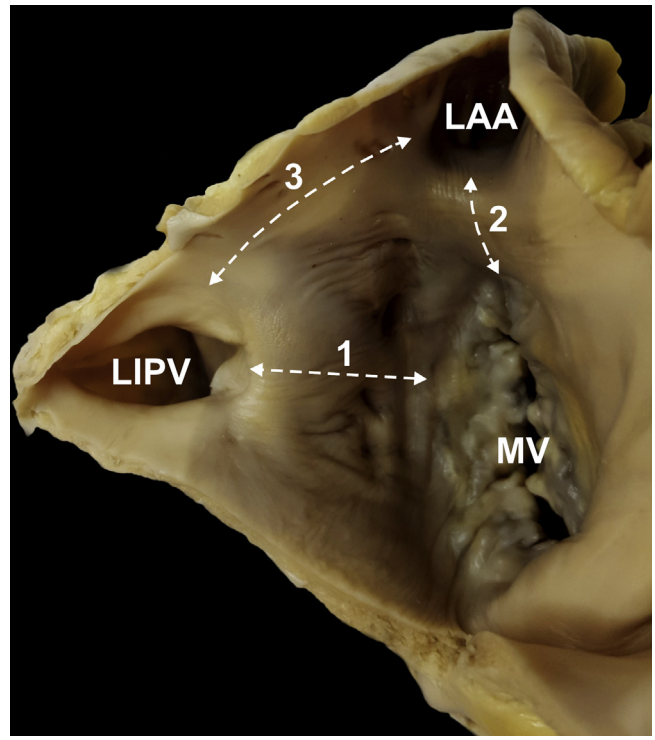

Fig. 1. Photograph of a cadaveric heart specimen showing the postero-inferior area of the lateral left atrial wall.
1—Mitral isthmus line; 2—left atrial appendage (LAA) isthmus line; 3—distance between the left inferior pulmonary vein (LIPV) ostium and the LAA orifice; MV—mitral valve.

We macroscopically evaluated the morphology of the postero-inferior area of the lateral left atrial wall from its endocardial surface. The mitral isthmus was defined as the shortest line between the inferior margin of the LIPV ostium and the margin of the mitral annulus, perpendicular to the mitral annulus, and its length was measured along the endocardial surface (Fig. 1). Additionally, the following measurements were made (Fig. 2):

- "Left" mitral isthmus length (LIM)—the shortest line between the left margin of the LIPV ostium and the margin of the mitral annulus, parallel to the mitral isthmus;
- "Right" mitral isthmus length (RIM)—the shortest line between the right margin of the LIPV ostium and the margin of the mitral annulus, parallel to the mitral isthmus;
- The transverse diameter of the LIPV ostium;
- The transverse diameter of the left atrial appendage (LAA) orifice, parallel to the mitral annulus;
- The shortest distance between the LAA orifice and the LIPV ostium (LAA–LIPV);
- LAA isthmus length—the shortest distance between the margin of the LAA orifice and the margin of the mitral annulus, perpendicular to the mitral annulus;
- The shortest distance between the margin of LAA orifice and the mitral isthmus line;

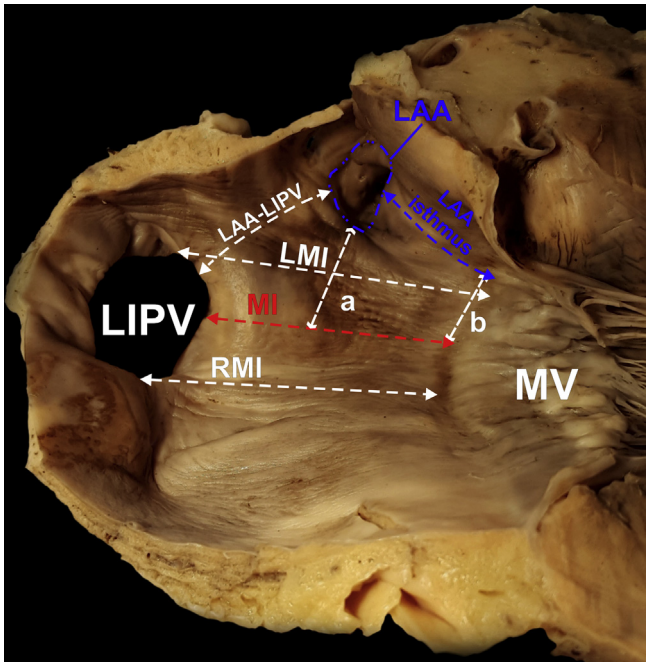

Fig. 2. Photograph of a cadaveric heart specimen showing the measurements lines within the studied region.
Measurements within the mitral isthmus (MI) and left atrial appendage (LAA) isthmus region were marked. a—The shortest distance between the margin of the LAA orifice and the mitral isthmus line; b—the shortest distance between the mitral and LAA isthmus lines; LAA–left inferior pulmonary vein (LIPV)—distance between the left atrial appendage orifice and the left inferior pulmonary vein ostium; LMI—left mitral isthmus; MV—mitral valve; RMI—right mitral isthmus.

- The shortest distance between the mitral and LAA isthmus lines;
- The medio-lateral and antero-posterior diameters of the mitral annulus.

In the case of LIPV absence, all measurements were referred to the common left pulmonary vein (CLPV) ostium (Klimek-Piotrowska et al., 2016). We used transillumination to macroscopically evaluate the arrangement of muscular components (i.e., crevices, diverticula, trabeculae, tissue bridges) of the left atrial wall within the mitral and LAA isthmus region.

2.3. Statistical analysis

We present the data as mean values with their corresponding standard deviations (SD) or as percentages, as well as median with interquartile range. The Shapiro–Wilk test was used to determine if the quantitative data were normally distributed and Levene's test was conducted to verify the homogeneity of variance. The Student's *t*-test and Mann–Whitney *U* test were used to compare structures between groups, and the paired Student's *t*-test and sign test were applied to compare two structures within each heart. We calculated correlation coefficients to measure the statistical dependence between the parameters of the measured hearts with scatter plots generated for selected cases. Comparison with results from other studies was conducting using the mean, SD, and number of cases (two-tailed test). We conducted our statistical analyses using STATISTICA v12 (StatSoft Inc., Tulsa, OK, USA). A p-value of less than .05 was taken to be statistically significant.

3. Results

The LIPV ostium was present in 179 hearts (89.5%), while the CLPV was found in the remaining 21 cases (10.5%). Table 1 shows

Table 1
Results of obtained measurements.

	All cases (N = 200)		Hearts with left inferior pulmonary vein (LIPV) (N = 179)							Hearts with common left pulmonary vein (CLPV) (N = 21)							p
	Mean	SD	Mean	SD	Min	Max	Median	Q_1	Q_3	Mean	SD	Min	Max	Median	Q_1	Q_3	
Age [years]	47.6	17.6	48.0	17.6	17.0	94.0	50.0	33.5	59.0	44.1	17.2	17.0	78.0	47.0	31.0	56.0	.337
Heart weight [g]	436.0	98.6	437.6	99.1	150.0	780.0	430.0	372.5	486.5	422.4	94.8	240.0	613.0	426.0	369.0	488.0	.565
BMI [kg/m^2]	26.8	4.5	26.9	4.5	13.3	50.6	26.4	24.3	29.0	26.3	4.0	17.5	33.1	26.2	23.3	29.4	.917
BSA [m^2]	1.9	.2	1.9	.2	1.5	2.5	1.9	1.8	2.1	1.9	.2	1.3	2.2	1.9	1.7	2.1	.613
Mitral isthmus [mm]	28.8	7.0	29.0	7.1	12.6	59.8	28.2	24.1	33.7	27.1	5.1	18.7	37.0	26.4	24.0	31.6	.216
Left mitral isthmus [mm]	31.7	8.0	32.0	8.2	7.7	60.5	32.2	26.2	36.1	29.1	5.9	16.0	39.1	28.5	26.2	33.0	.111
Right mitral isthmus [mm]	32.7	7.7	32.8	7.8	10.4	57.7	32.8	26.9	36.8	31.8	6.7	23.7	51.4	31.2	26.2	33.7	.461
Transverse diameter of LIPV or CLPV ostium [mm]	14.3	3.5	13.8	3.2	6.6	26.6	13.5	11.6	15.9	18.3	3.5	12.7	27.5	17.3	16.1	19.7	.000
Transverse diameter of LAA orifice [mm]	12.9	4.5	13.0	4.6	2.6	31.3	13.3	10.0	16.0	12.6	4.3	4.2	18.7	14.4	10.1	16.2	.991
Distance between LAA orifice and LIPV or CLPV ostium [mm]	18.4	7.8	18.4	8.0	2.1	44.3	18.4	11.8	24.1	18.4	6.4	7.1	30.5	19.4	13.9	22.2	.992
LAA isthmus [mm]	14.2	4.8	14.0	4.8	5.1	31.2	13.5	10.5	16.8	16.0	4.3	8.4	22.9	15.9	13.2	20.0	.037
Distance between LAA orifice and mitral isthmus line [mm]	18.4	6.8	18.6	6.7	3.0	52.1	17.8	14.3	21.6	16.4	7.6	7.4	38.2	13.5	11.4	21.3	.063
Distance between mitral and LAA isthmus lines [mm]	15.7	4.5	15.8	4.4	6.9	34.8	15.2	12.8	18.0	15.1	4.9	10.3	27.5	13.8	11.8	17.3	.229
Medio-lateral diameter of mitral valve [mm]	22.4	6.5	22.1	6.5	5.3	38.7	22.8	17.3	26.8	24.8	5.6	14.0	35.4	25.2	21.6	28.4	.098
Antero-posterior diameter of mitral annulus[a] [mm]	22.0	5.6	22.0	5.7	7.2	37.5	21.5	17.9	26.0	21.7	5.4	12.4	34.2	20.6	20.2	23.1	.905

N—number of samples; SD—standard deviation; Q_1 and Q_3—lower and upper quartiles; BMI—body mass index; BSA—body surface area; LAA—left atrial appendage.
[a] Perpendicular to the medio-lateral diameter.

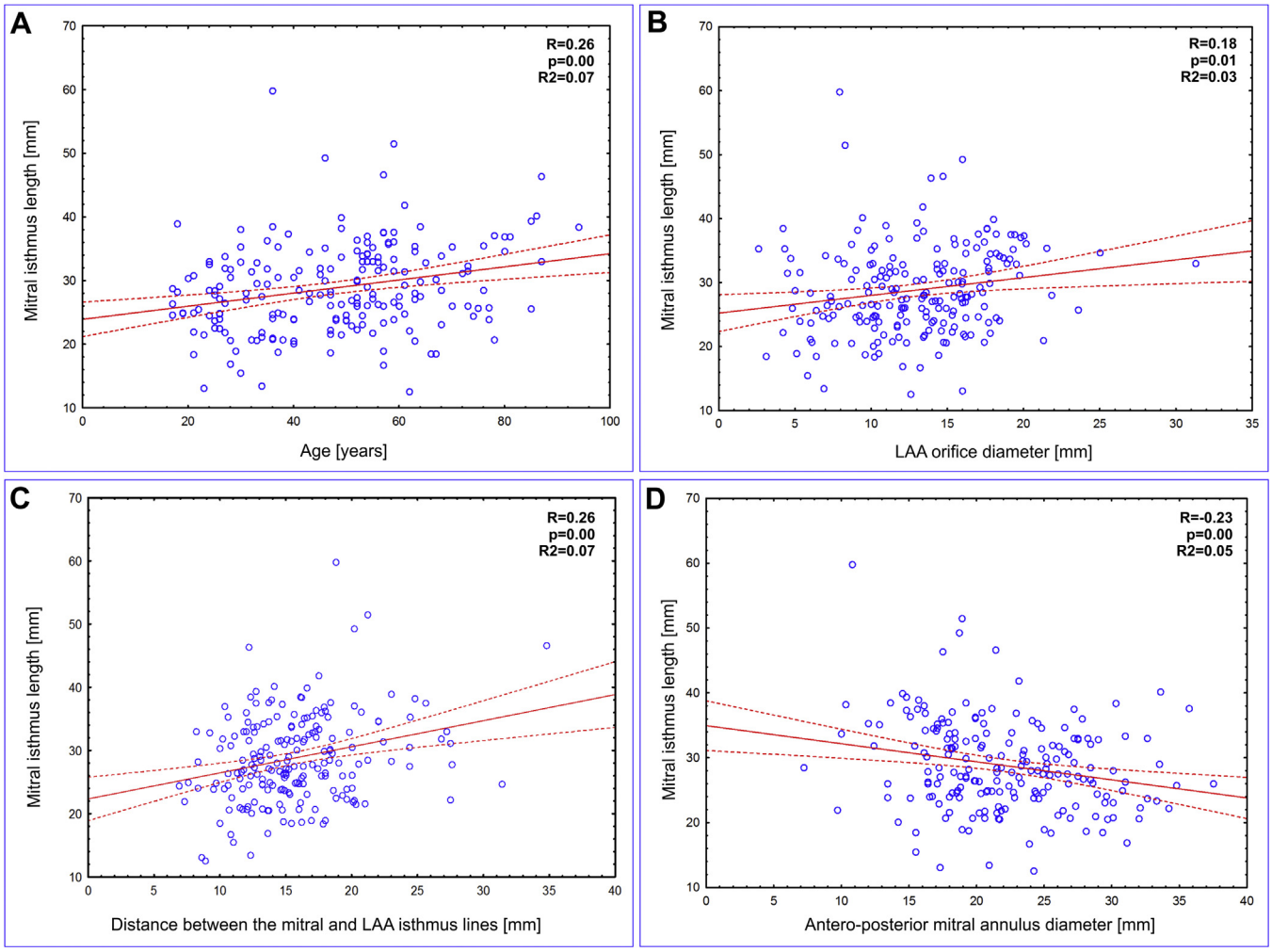

Fig. 3. Scatter plots of mitral isthmus length and (A) age; (B) left atrial appendage (LAA) orifice diameter; (C) distance between the mitral and LAA isthmus lines; (D) antero-posterior mitral annulus diameter.

the results of all obtained measurements within the studied area. The diameter of the CLPV was significantly greater than the ostium diameter of the LIPV ($p < .0001$). Surprisingly, there were no significant differences in the length of the mitral isthmus or any other parameter between these groups except for the LAA isthmus, which was longer in hearts with the CLPV ($p = .037$).

The mitral isthmus was significantly longer than the LAA isthmus ($p = .00$) and shorter than the left ($p = .00$) and right ($p = .00$) mitral isthmus lines. The length of the mitral isthmus was correlated with the donor's age ($r = .26$; $p = .00$), LAA orifice diameter ($r = .18$; $p = .01$), the distance between the mitral and LAA isthmus lines ($r = .26$; $p = .00$), and inversely correlated with the antero-posterior mitral annulus diameter ($r = -.23$; $p = .00$) (Fig. 3). The left mitral isthmus was significantly shorter than the right one ($p = .01$). Both the length of the right and left mitral isthmus were correlated with the donor's age ($r = .34$; $p = .00$ and $r = .33$; $p = .00$), LAA orifice diameter ($r = .19$; $p = .01$ and $r = .26$; $p = .00$), and the distance between the mitral and LAA isthmus lines ($r = .37$; $p = .00$ and $r = .34$; $p = .00$) (Fig. 4). Additionally, the right mitral isthmus length was inversely correlated with the antero-posterior mitral annulus diameter ($r = -.21$; $p = .003$).

In 97% of hearts the mitral isthmus was longer than the LAA isthmus, with a mean difference in length of 15.2 ± 7.6 mm (range: .1–53.6 mm). In 67% of hearts the LAA isthmus was twice and more shorter than mitral isthmus and in 7% of hearts it was even four times shorter. The mean length of the LAA isthmus was significantly shorter than the right and left mitral isthmus lines ($p = .00$ and $p = .00$ respectively). The LAA isthmus length was correlated with donors age ($r = .17$; $p = .01$). The LAA orifice was located inferior to (61.0%), at the same level as (35.0%), or superior to (4.0%) the pulmonary vein (LIPV or CLPV) ostium. For the hearts with LAA orifice located inferior to the pulmonary vein ostium, the mitral isthmus was significantly longer than for the remaining cases ($p = .00$). The LAA orifice was intersected by the left mitral isthmus in 4% of cases and was intersected by mitral isthmus line in 1.5% of cases (Fig. 5).

The distance between the LAA orifice and the LIPV ostium is longer than the LAA isthmus ($p = .00$) and shorter than the mitral isthmus ($p = .00$) (Fig. 6). It was correlated with the donor's age ($r = .27$; $p = .00$), heart weight ($r = .26$; $p = .00$), and the medio-lateral diameter of the mitral valve annulus ($r = .37$; $p = .00$) (Fig. 7A–C). The heart weight was correlated with the medio-lateral diameter of the mitral annulus ($r = .33$; $p = .00$) but not with the antero-posterior diameter. The distance between the mitral and LAA isthmus lines was the shortest at the level of mitral annulus and increased gradually toward the LIPV ostium. The distance between the mitral and LAA isthmus lines was correlated with the donor's age ($r = .21$; $p = .00$), heart weight ($r = .18$; $p = .01$), and with the distance between the LAA orifice and the LIPV ostium ($r = .21$; $p = .00$)

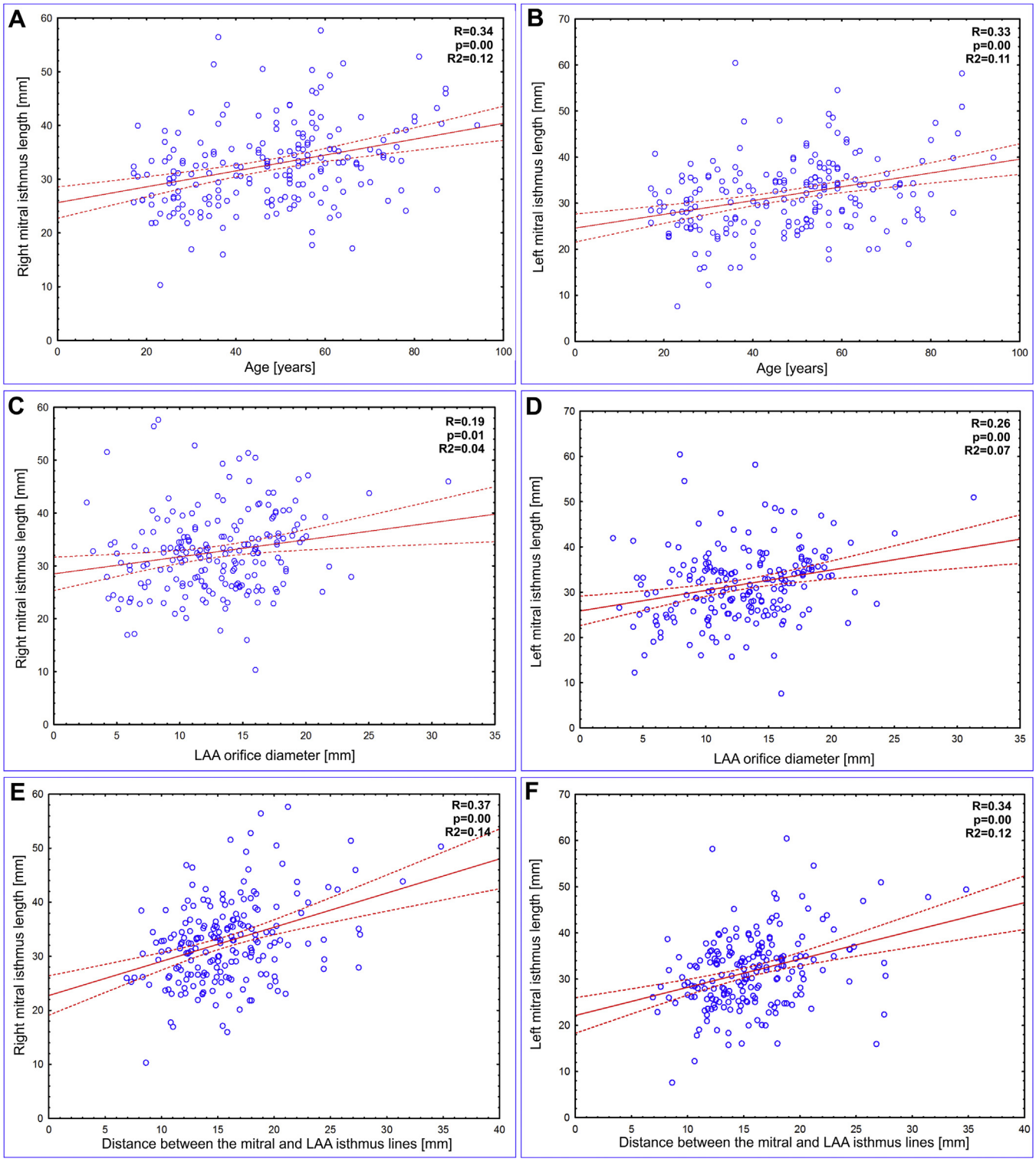

Fig. 4. Scatter plots of (A) age and right mitral isthmus length; (B) age and left mitral isthmus length; (C) left atrial appendage (LAA) orifice diameter and right mitral isthmus length; (D) LAA orifice diameter and left mitral isthmus length; (E) distance between the mitral and LAA isthmus lines and right mitral isthmus length; (F) distance between the mitral and LAA isthmus lines and left mitral isthmus length.

(Fig. 7D–F). There were no significant differences between the sexes in any of the measured diameters of mitral isthmus region, nor were there significant correlations with donor's weight, BMI, or BSA.

In 65.5% of all studied hearts the area between the right and left mitral isthmus lines was completely smooth. In the remaining hearts we observed differently-organized muscular and membranous structures, which can be roughly classified as: crevices and diverticula (18.0%), intertrabecular recesses (7.0%), and trabecular bridges (3.5%). In 6% of hearts we observed combinations of the foregoing structures. There was no difference in the mitral isthmus length between the hearts with smooth mitral isthmus and those with additional structures ($p = .22$), whereas the LAA isthmus was longer in hearts with smooth mitral isthmus ($p = .01$). In 69.5% of hearts, the region between the left and right mitral isthmuses was

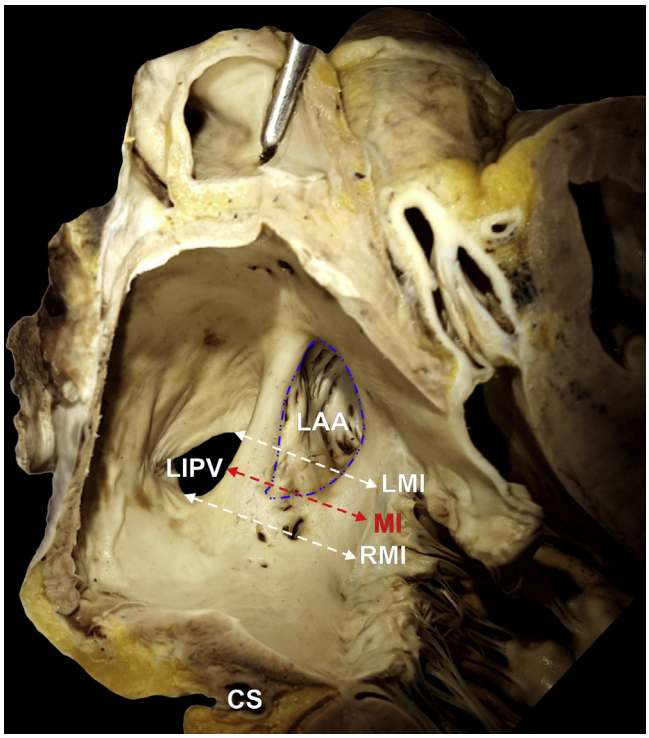

Fig. 5. Photograph of a cadaveric heart specimen where the left atrial appendage (LAA) orifice is intersected by the left mitral isthmus (LMI) and by the mitral isthmus (MI) line.
CS—coronary sinus; LIPV—left inferior pulmonary vein; RMI—right mitral isthmus.

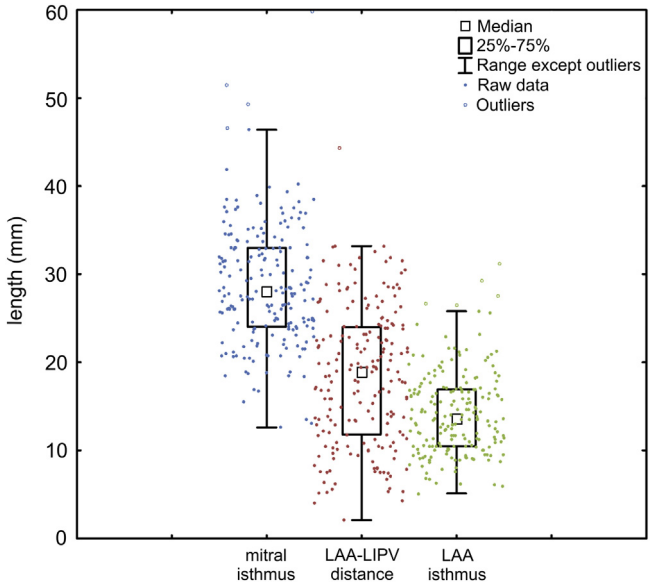

Fig. 6. Raw data overlaid with a box-and-whiskers plot for the (a) mitral isthmus length, (b) distance between the left atrial appendage (LAA) orifice and the left inferior pulmonary vein ostium (LAA–LIPV) and (c) the LAA isthmus length.

concave. The LAA isthmus line was smooth in 95.5% of all cases, with only small crevices in remaining 4.5% (Fig. 8).

4. Discussion

From an anatomical perspective, the mitral isthmus is not a separate entity but rather a line drawn on the endocardial surface of the left atrium. Nevertheless, its clinical significance is huge. Until this point, the normal anatomy of the mitral isthmus region has only been investigated using few dozen autopsied heart specimens (Becker, 2004; Cho et al., 2012; Wittkampf et al., 2005). In his study of 20 human hearts, Becker (2004) concluded that the mitral isthmus was diverse and 34.6 ± 10.0 mm in length. Wittkampf et al. (2005) performed an anatomo-histological study on 16 heart specimens and found a mean mitral isthmus length of 35.0 ± 7.0 mm. In the aforementioned studies, the mitral isthmus length was significantly longer than in the present study ($p = .00$ and $p = .00$, respectively). An examination of 10 hearts by Cho et al. (2012) measured the mitral isthmus as 31.0 ± 6.0 mm in length, which does not differ significantly from our results ($p = .33$).

Additionally, several computed tomography-based studies investigated this heart region. Cismaru et al. (2015) measured the mitral isthmus of 46 patients with AF (29 ± 11.2 mm), however their results are similar to present study on non-AF hearts ($p = .65$). A study by Cho et al. revealed that the mitral isthmus line was 36.4 + 8.6 mm in length and was the shortest of three studied lines (i.e., the mitral isthmus, anteromedial line, and anterolateral line). Also, mitral isthmus length did not significantly differ by the presence of AF (Cho et al., 2012). On the other hand, Chiang et al. (2006) found that the mitral isthmus is longer in patients with paroxysmal AF (33.0 ± 6.8 vs 27.1 ± 6.0 mm, $p < .001$) and moreover is shorter than the medial isthmus (between right inferior pulmonary vein and mitral annulus).

Anatomical conditions in the mitral isthmus region may significantly influence the ablation procedure and be the cause of the divergent clinical results and recommendations. Achieving a continuous ablation line and bidirectional conduction block within the mitral isthmus is technically challenging for several reasons. First, the presence of blood vessels (i.e., the grate cardiac vein and left circumflex artery) within the mitral isthmus line affects ablation in three ways. Intramural blood flow in this vessel may act as an epicardial "heat sink." removing heat from the ablation site by convective cooling, thus reducing the efficacy of mitral isthmus ablation (Wittkampf et al., 2005; Wong and Betts, 2012; Wong et al., 2011a). Additionally, myocardial sleeves around the coronary sinus, great cardiac, and Marshall veins may act as an epicardial connection that could bridge the lesion line (Chauvin et al., 2000). On the other hand, the great proximity of blood vessels forces the use of lower radiofrequency energy to avoid several complications such as left circumflex artery injury (Wong et al., 2011c). Second, the mitral isthmus is not a straight, flat line, but is mostly concave (69.5–80.0%) or even has a pouch (4.4–20%), which results in diminished catheter stability and poor tissue contact (Chiang et al., 2006; Cho et al., 2012; Yokokawa et al., 2011). Both the depth of the mitral isthmus and the prevalence of a pouch were higher in patients with incomplete blocks than in those with complete isthmus blocks (Yokokawa et al., 2011). Third, the presence of differently-organized muscular and membranous structures (e.g., crevices, recesses, muscular bridges, etc.), which are remnants of the pectinate muscles that extended from the LAA, has a huge impact on mitral isthmus ablation. Wittkampf et al. (2005) found small crevices within the mitral isthmus region in 94% of all studied cases. Furthermore, Cabrera et al. (2008) noticed that some muscle bundles were separated by crevices or crevices and pits alone in 45% of all hearts. In the present study, unwanted structures within the mitral isthmus that could entrap the tip of an ablation catheter were present in 34.5% of hearts. The gaps between the bridges and the proper atrial wall can negatively influence the mitral isthmus ablation, and more energy may be required to reach the isthmus block. On the contrary, higher energy may damage the very thin tissue inside the crevices and thus lead to cardiac tamponade (Cabrera et al., 2012). Finally, the height takeoff of LIPV and longer mitral isthmus length is associated with significantly lower ablation success rates or higher AF recurrence (Kiuchi et al., 2015; Scherr et al., 2015; Takatsuki et al., 2009; Wong et al., 2011b).

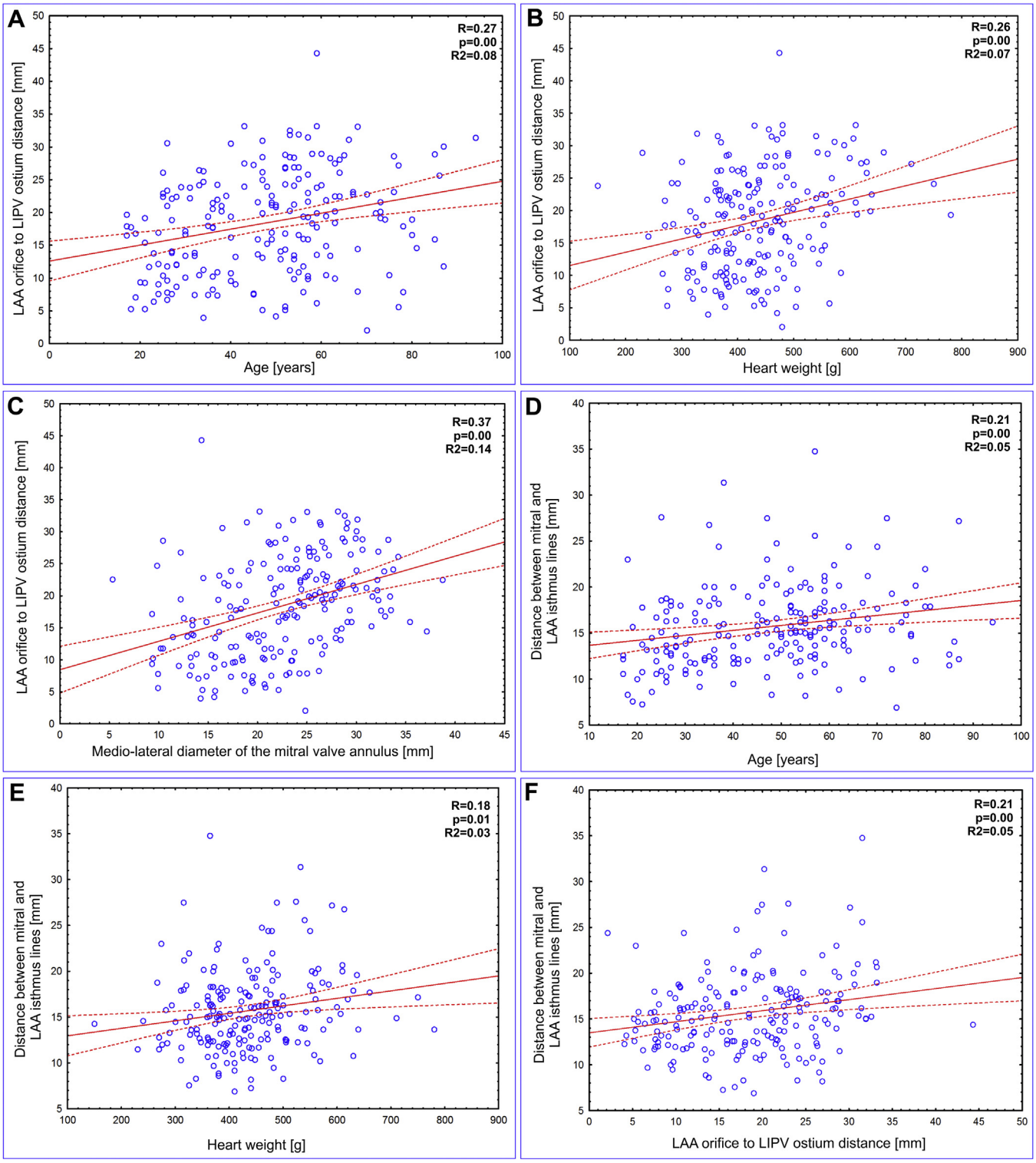

Fig. 7. Scatter plots of the distance between the left atrial appendage (LAA) orifice and the left inferior pulmonary vein (LIPV) ostium and: (A) age; (B) heart weight; (C) medio-lateral diameter of the mitral valve annulus; as well as of the distance between the mitral and LAA isthmus lines and: (D) age; (E) heart weight; (F) LAA orifice to LIPV ostium distance.

We hypothesize that, in some cases, the mitral isthmus may be replaced by ablation in the LAA isthmus, or those two lines may be ablated together to achieve better results. It has been proven that the LAA is responsible for the recurrence of AF/tachycardia in about one-third of patients presenting for repeat ablation procedures, thus the LAA isthmus line may be useful as an additional line during LAA electrical isolation (Di Biase et al., 2010; Panikker et al., 2016). The LAA isthmus is significantly shorter than the mitral isthmus, and in almost all cases it is smooth. We can confirm that this line is the shortest line between the mitral annulus and any other anatomical structure inside the left atrium (Cismaru et al., 2015). It is located on the anterior margin of the LAA orifice, which is the thickest place around the LAA (Panikker et al., 2016). Because of the thin wall of the LAA, caution should be taken when the ablation

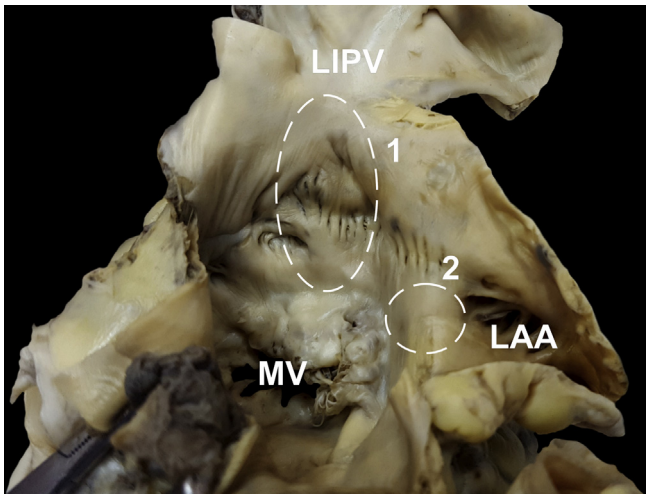

Fig. 8. Photograph of a cadaveric heart specimen showing the mitral isthmus area with multiple undesirable structures (1) and smooth left atrial appendage (LAA) isthmus region (2).
LIPV—left inferior pulmonary vein; MV—mitral valve.

is performed in the grate proximity of the LAA orifice. However, the LAA walls are not paper thin, and are certainly thicker than the atrial wall inside the crevices in the mitral isthmus area (Cabrera et al., 2008). Little is known about the spatial relationship of blood vessels within the LAA isthmus line, nevertheless in this area we should expect only the left circumflex artery (but situated at a safe distance), as well as some smaller veins without myocardial sleeves (Wittkampf et al., 2005). Further studies are required to evaluate the clinical value of the LAA isthmus line.

The main limitation of this study is that all measurements were made on autopsied heart specimens after formaldehyde fixation, which may have resulted in slight changes in the size and shape of the heart. However, prior studies have proven that the use of 10% paraformaldehyde does not cause significant changes in atrial tissue dimensions; the dimensions of fixed hearts are similar to those before fixation (Hołda et al., 2016). In addition, postmortem studies may not directly correlate with in vivo tissue physiology. Therefore, we can draw no conclusions about the behavior and dimension changes of the studied area within the cardiac cycle. Additionally, the heart specimens were dissected from patients without atrial fibrillation and thus only represent the normal anatomy of the infero-lateral left atrium. However, we believe that these limitations do not impede the morphological analysis of relationships between individual heart structures and their relative dimensions.

5. Conclusion

To our best knowledge, this is the most complex morphometric description of the postero-inferior area of the lateral left atrial wall that takes into account several different endocardial lines and mutual anatomical relationships between the LIPV ostium and LAA orifice. Regardless of the anatomical variants of the left-sided pulmonary veins, the mitral isthmus area is quite uniform in size. We proposed the LAA isthmus line for potential clinical use. The LAA isthmus is considerably shorter than the mitral isthmus. The mitral isthmus line has many unwanted structures that may entrap the catheter, which is not the case for the LAA isthmus.

Appendix A. Supplementary data

Supplementary data associated with this article can be found, in the online version, at http://dx.doi.org/10.1016/j.aanat.2016.11.011.

References

Becker, A.E., 2004. Left atrial isthmus: anatomic aspects relevant for linear catheter ablation procedures in humans. J. Cardiovasc. Electrophysiol. 15, 809–812, http://dx.doi.org/10.1046/j.1540-8167.2004.03651.x.

Cabrera, J.A., Ho, S.Y., Climent, V., Sánchez-Quintana, D., 2008. The architecture of the left lateral atrial wall: a particular anatomic region with implications for ablation of atrial fibrillation. Eur. Heart J. 29, 356–362, http://dx.doi.org/10.1093/eurheartj/ehm606.

Cabrera, J.A., Pizarro, G., Sánchez-Quintana, D., 2012. Muscular architecture of the mitral isthmus: anatomical determinants for catheter ablation. Europace 14, 1069–1071, http://dx.doi.org/10.1093/europace/eus176.

Calkins, H., Kuck, K.H., Cappato, R., Brugada, J., Camm, A.J., Chen, S.A., Crijns, H.J., Damiano, R.J., Davies, D.W., DiMarco, J., Edgerton, J., Ellenbogen, K., Ezekowitz, M.D., Haines, D.E., Haissaguerre, M., Hindricks, G., Iesaka, Y., Jackman, W., Jalife, J., Jais, P., Kalman, J., Keane, D., Kim, Y.H., Kirchhof, P., Klein, G., Kottkamp, H., Kumagai, K., Lindsay, B.D., Mansour, M., Marchlinski, F.E., McCarthy, P.M., Mont, J.L., Morady, F., Nademanee, K., Nakagawa, H., Natale, A., Nattel, S., Packer, D.L., Pappone, C., Prystowsky, E., Raviele, A., Reddy, V., Ruskin, J.N., Shemin, R.J., Tsao, H.M., Wilber, D., Fibrillation HRSTFoCaSAoA, 2012. 2012 HRS/EHRA/ECAS expert consensus statement on catheter and surgical ablation of atrial fibrillation: recommendations for patient selection, procedural techniques, patient management and follow-up, definitions, endpoints, and research trial design: a report of the Heart Rhythm Society (HRS) Task Force on Catheter and Surgical Ablation of Atrial Fibrillation. Developed in partnership with the European Heart Rhythm Association (EHRA), a registered branch of the European Society of Cardiology (ESC) and the European Cardiac Arrhythmia Society (ECAS); and in collaboration with the American College of Cardiology (ACC), American Heart Association (AHA), the Asia Pacific Heart Rhythm Society (APHRS), and the Society of Thoracic Surgeons (STS). Endorsed by the governing bodies of the American College of Cardiology Foundation, the American Heart Association, the European Cardiac Arrhythmia Society, the European Heart Rhythm Association, the Society of Thoracic Surgeons, the Asia Pacific Heart Rhythm Society, and the Heart Rhythm Society. Heart Rhythm 9, 632–696, http://dx.doi.org/10.1016/j.hrthm.2011.12.016, e621.

Chauvin, M., Shah, D.C., Haïssaguerre, M., Marcellin, L., Brechenmacher, C., 2000. The anatomic basis of connections between the coronary sinus musculature and the left atrium in humans. Circulation 101, 647–652.

Chiang, S.J., Tsao, H.M., Wu, M.H., Tai, C.T., Chang, S.L., Wongcharoen, W., Lin, Y.J., Lo, L.W., Chen, Y.J., Sheu, M.H., Chang, C.Y., Chen, S.A., 2006. Anatomic characteristics of the left atrial isthmus in patients with atrial fibrillation: lessons from computed tomographic images. J. Cardiovasc. Electrophysiol. 17, 1274–1278, http://dx.doi.org/10.1111/j.1540-8167.2006.00645.x.

Cho, Y., Lee, W., Park, E.A., Oh, I.Y., Choi, E.K., Seo, J.W., Oh, S., 2012. The anatomical characteristics of three different endocardial lines in the left atrium: evaluation by computed tomography prior to mitral isthmus block attempt. Europace 14, 1104–1111, http://dx.doi.org/10.1093/europace/eus051.

Cismaru, G., Rosu, R., El Kamar, N., Muresan, L., Puiu, M., Andronache, M., Puie, P., Matuz, R., Gusetu, G., Pop, D., Mircea, P.A., Zdrenghea, D., 2015. Distance between the left atrial appendage and mitral annulus evaluated by CARTO 3 integrated computed tomography imaging. Med. Princ. Pract. 24, 555–559, http://dx.doi.org/10.1159/000431371.

de Vasconcelos, J.T., Costa, E.R., dos Santos Galvão Filho, S., Barcellos, C.M., Maldonado, J.G., 2002. Block of the mitral-pulmonary isthmus during ablation of a single left-sided accessory pathway causing different patterns of retrograde atrial activation. Arq. Bras. Cardiol. 78, 497–509.

Di Biase, L., Burkhardt, J.D., Mohanty, P., Sanchez, J., Mohanty, S., Horton, R., Gallinghouse, G.J., Bailey, S.M., Zagrodzky, J.D., Santangeli, P., Hao, S., Hongo, R., Beheiry, S., Themistoclakis, S., Bonso, A., Rossillo, A., Corrado, A., Raviele, A., Al-Ahmad, A., Wang, P., Cummings, J.E., Schweikert, R.A., Pelargonio, G., Dello Russo, A., Casella, M., Santarelli, P., Lewis, W.R., Natale, A., 2010. Left atrial appendage: an underrecognized trigger site of atrial fibrillation. Circulation 122, 109–118, http://dx.doi.org/10.1161/CIRCULATIONAHA.109.928903.

Hołda, M., Klimek-Piotrowska, W., Koziej, M., Piątek, K., Hołda, J., 2016. Influence of different fixation protocols on the preservation and dimensions of cardiac tissue. J. Anat. 229 (2), 334–340.

Kirchhof, P., Calkins, H., 2016. Catheter ablation in patients with persistent atrial fibrillation. Eur. Heart J., http://dx.doi.org/10.1093/eurheartj/ehw260, Epub ahead of print – 2016 Jul 7. pii: ehw260.

Kiuchi, K., Yoshida, A., Takei, A., Fukuzawa, K., Itoh, M., Imamura, K., Fujiwara, R., Suzuki, A., Nakanishi, T., Yamashita, S., Hirata, K., Kanda, G., Okajima, K., Shimane, A., Yamada, S., Taniguchi, Y., Yasaka, Y., Kawai, H., 2015. Topographic variability of the left atrium and pulmonary veins assessed by 3D-CT predicts the recurrence of atrial fibrillation after catheter ablation. J. Arrhythm. 31, 286–292, http://dx.doi.org/10.1016/j.joa.2015.03.006.

Klimek-Piotrowska, W., Hołda, M.K., Piątek, K., Koziej, M., Hołda, J., 2016. Normal distal pulmonary vein anatomy. PeerJ 4, e1579, http://dx.doi.org/10.7717/peerj.1579.

Luria, D.M., Nemec, J., Etheridge, S.P., Compton, S.J., Klein, R.C., Chugh, S.S., Munger, T.M., Shen, W.K., Packer, D.L., Jahangir, A., Rea, R.F., Hammill, S.C., Friedman, P.A., 2001. Intra-atrial conduction block along the mitral valve annulus during accessory pathway ablation: evidence for a left atrial "isthmus". J. Cardiovasc. Electrophysiol. 12, 744–749.

Matsuo, S., Wright, M., Knecht, S., Nault, I., Lellouche, N., Lim, K.T., Arantes, L., O'Neill, M.D., Hocini, M., Jaïs, P., Haïssaguerre, M., 2010. Peri-mitral atrial flutter in patients with atrial fibrillation ablation. Heart Rhythm 7, 2–8, http://dx.doi.org/10.1016/j.hrthm.2009.09.067.

Oral, H., Scharf, C., Chugh, A., Hall, B., Cheung, P., Good, E., Veerareddy, S., Pelosi, F., Morady, F., 2003. Catheter ablation for paroxysmal atrial fibrillation: segmental pulmonary vein ostial ablation versus left atrial ablation. Circulation 108, 2355–2360, http://dx.doi.org/10.1161/01.CIR.0000095796.45180.88.

Panikker, S., Jarman, J.W., Virmani, R., Kutys, R., Haldar, S., Lim, E., Butcher, C., Khan, H., Mantziari, L., Nicol, E., Foran, J.P., Markides, V., Wong, T., 2016. Left atrial appendage electrical isolation and concomitant device occlusion to treat persistent atrial fibrillation: a first-in-human safety, feasibility, and efficacy study. Circ. Arrhythm. Electrophysiol. 9, http://dx.doi.org/10.1161/CIRCEP.115.003710.

Scherr, D., Derval, N., Sohal, M., Pascale, P., Wright, M., Jadidi, A., Komatsu, Y., Roten, L., Wilton, S.B., Pedersen, M., Ramoul, K., Miyazaki, S., Shah, A., Linton, N., Manninger, M., Denis, A., Hocini, M., Sacher, F., Haissaguerre, M., Jais, P., Knecht, S., 2015. Length of the mitral isthmus but not anatomical location of ablation line predicts bidirectional mitral isthmus block in patients undergoing catheter ablation of persistent atrial fibrillation: a randomized controlled trial. J. Cardiovasc. Electrophysiol. 26, 629–634, http://dx.doi.org/10.1111/jce.12667.

Takatsuki, S., Extramiana, F., Hayashi, M., Haggui, A., Messali, A., Milliez, P., Leenhardt, A., Cauchemez, B., 2009. High take-off left inferior pulmonary vein as an obstacle in creating a conduction block at the lateral mitral isthmus. Europace 11, 910–916, http://dx.doi.org/10.1093/europace/eup151.

Verma, A., Jiang, C.Y., Betts, T.R., Chen, J., Deisenhofer, I., Mantovan, R., Macle, L., Morillo, C.A., Haverkamp, W., Weerasooriya, R., Albenque, J.P., Nardi, S., Menardi, E., Novak, P., Sanders, P., Investigators SAI, 2015. Approaches to catheter ablation for persistent atrial fibrillation. N. Engl. J. Med. 372, 1812–1822, http://dx.doi.org/10.1056/NEJMoa1408288.

Wittkampf, F.H., van Oosterhout, M.F., Loh, P., Derksen, R., Vonken, E.J., Slootweg, P.J., Ho, S.Y., 2005. Where to draw the mitral isthmus line in catheter ablation of atrial fibrillation: histological analysis. Eur. Heart J. 26, 689–695, http://dx.doi.org/10.1093/eurheartj/ehi095.

Wong, K.C., Betts, T.R., 2012. A review of mitral isthmus ablation. Indian Pacing Electrophysiol. J. 12, 152–170.

Wong, K.C., Jones, M., Qureshi, N., Sadarmin, P.P., De Bono, J., Rajappan, K., Bashir, Y., Betts, T.R., 2011a. Balloon occlusion of the distal coronary sinus facilitates mitral isthmus ablation. Heart Rhythm 8, 833–839, http://dx.doi.org/10.1016/j.hrthm.2011.01.042.

Wong, K.C., Jones, M., Sadarmin, P.P., De Bono, J., Qureshi, N., Rajappan, K., Bashir, Y., Betts, T.R., 2011b. Larger coronary sinus diameter predicts the need for epicardial delivery during mitral isthmus ablation. Europace 13, 555–561, http://dx.doi.org/10.1093/europace/eur019.

Wong, K.C., Lim, C., Sadarmin, P.P., Jones, M., Qureshi, N., De Bono, J., Rajappan, K., Bashir, Y., Betts, T.R., 2011c. High incidence of acute sub-clinical circumflex artery 'injury' following mitral isthmus ablation. Eur. Heart J. 32, 1881–1890, http://dx.doi.org/10.1093/eurheartj/ehr117.

Yokokawa, M., Sundaram, B., Garg, A., Stojanovska, J., Oral, H., Morady, F., Chugh, A., 2011. Impact of mitral isthmus anatomy on the likelihood of achieving linear block in patients undergoing catheter ablation of persistent atrial fibrillation. Heart Rhythm 8, 1404–1410, http://dx.doi.org/10.1016/j.hrthm.2011.04.030.